

Nurol Arık, Tekin Akpolat  
Fatih Demirkan, Figen Demirkazık  
Ünal Yasavul, Çetin Turgan  
Şali Çağlar

Department of Nephrology,  
Hacettepe University School of Medicine,  
Ankara, Turkey

## Mediastinal Hematoma: A Rare Complication of Subclavian Catheterization for Hemodialysis

Dear Sir,

Subclavian vein catheterization was first introduced in the late 1970s and has become a preferred method of temporary vascular access for acute hemodialysis. Now, it is widely used all over the world. However, acute complications such as hemothorax, pneumothorax, atrial perforation, air embolism and delayed complications such as stenosis and bacteremia associated with the placement of catheters continue to occur [1]. This report describes a rare complication of subclavian catheter insertion for hemodialysis in a patient with end-stage renal failure.

A 51-year-old man with chronic renal failure was started on chronic hemodialysis in July 1986. He underwent cadaveric renal transplantation in November 1989. As a result of graft loss due to chronic rejection, the patient returned to a hemodialysis program by arteriovenous fistula which was formed at the wrist in his left arm in June 1990. He had been hospitalized because of fistula occlusion, and a new fistula was created at the wrist in his right arm on December 7, 1991. While awaiting the maturation of the new fistula, he developed symptoms of hypervolemia. So, it was decided to place a subclavian hemodialysis catheter for immediate access. Before the placement of the catheter, a chest x-ray was taken and showed no abnormality except for cardiac enlargement present on previous radiographs. A double-lumen hemodialysis catheter was inserted via the left subclavian vein using the Seldinger technique. Following the procedure the patient complained about shortness of breath; subsequently dyspnea increased, and orthopnea appeared within a few hours after the insertion of the catheter. A marked reduction of blood pressure was recorded as well. A postinsertion chest x-ray revealed a large opacity covering the media-

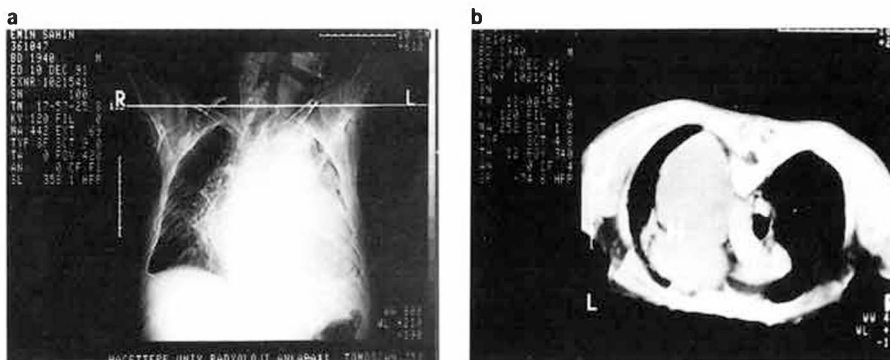


Fig. 1a, b CT scans of the thorax demonstrating a large mediastinal hematoma (H).

stinum and almost all the left hemithorax. The trachea was displaced towards the right hemithorax. No pericardial effusion was detected by echocardiography. A CT scan of the chest suggested the abnormality to be a large mediastinal hematoma extending to the left hemithorax (fig. 1a, b). The patient died of hypovolemic shock in spite of all the efforts including drainage of the hematoma, blood transfusion and other supportive measures undertaken immediately.

Mortality due to fatal complications (e.g. bacteremia, hemothorax, air embolism) related with subclavian catheterization for hemodialysis has been reported to be between 0 and 1.25/1,000 catheterizations [1]. We are reporting a case with chronic renal failure who had mediastinal hematoma leading to death after subclavian catheterization. This complication has been rarely reported before in uremic patients undergoing subclavian vein cannulation for hemodialysis [2, 3].

We can only speculate as to the possible mechanism of this rare complication. It is likely that the guide wire used during cath-

eterization might have penetrated the vessel wall; subsequently, leakage of blood resulted in mediastinal hematoma. We conclude that although percutaneous catheterization of the subclavian vein has become a method of choice for temporary vascular access in uremic patients who need acute hemodialysis, it is not free of complications which can lead to death. Thus, one must stress the great respect deserved by those performing these procedures.

### References

- 1 Vanholder R, Hoenich N, Ringoir S: Morbidity and mortality of central venous catheter hemodialysis: A review of 10 years' experience. *Nephron* 1987;47:274-279.
- 2 Vaziri ND, Maksy M, Lewis M, Martin D, Edwards K: Massive mediastinal hematoma caused by a double-lumen subclavian catheter. *Artif Organs* 1984;8:223-226.
- 3 Masud T, Tapson JS: Mediastinal haematoma caused by subclavian catheterization for hemodialysis. *Int J Artif Organs* 1989;12:708-710.